

# Comparative Effects of Estrogen, Testosterone, and Progesterone on Benign Mammary Tumors of the Rat\*

Jacob Heiman, M.D.

(From the Department of Cancer Research, College of Physicians and Surgeons, Columbia University, New York, N. Y.)

(Received for publication July 10, 1942)

The effects of estrogens and androgens on the growth of benign fibroadenoma have already been reported (6, 8). The present record deals with the effects on similar tumors of progesterone, and compares the effects of estrogen, androgen, and progesterone injected singly or in combination.<sup>1</sup> An attempt has been made to duplicate on tumors the effect of progesterone acting synergistically with estrogen on either the duct or alveolar system, or both, of the mammary gland in early pregnancy.

## EXPERIMENTAL

Intact and castrated male and female rats with spontaneous benign tumors or auto- or homotransplants were injected with progesterone. Some were treated with estrogen previously, some simultaneously, and some received only progesterone. Two pregnant rats with benign tumors were also given progesterone. The total dosage varied between 9 and 18 mgm. of progesterone and 1 to 2.5 mgm. of estrogen. Sixty rats were used, including 4 with spontaneous tumors and 2 pregnant ones.

Before injections of estrogen or progesterone were begun 4 Wistar rats of our laboratory strain and bearing spontaneous tumors were inoculated with autotransplants. This gave an opportunity to study 3 to 4 growing or receding tumors of similar morphology in one rat. In these 4 rats there were available 12 autotransplants of the first generation, 6 of the second generation, and 2 of the third. In this way the aging of the tumor was slowed, and observation could be carried out on small tumors instead of on bulky ones (9).

\* Presented at the Endocrine-Cancer Conference, Atlantic City, June 5, 1942.

<sup>1</sup> Dimenformon benzoate was generously supplied by Roche-Organon, Inc., Nutley, N. J.; progesterone and testosterone by Ciba Pharmaceutical Products, Inc., Summit, N. J., Roche-Organon, Inc., Nutley, N. J., and Schering Corporation, Bloomfield, N. J.

Autotransplants were put into 4 and homotransplants into 60 Wistar animals, divided into the following series:

- (a) Four females with spontaneous tumors.
- (b) Thirty-eight normal females (2 pregnancies).
- (c) Six castrated females and 6 normal males.
- (d) Twelve castrated males.

*Group I.*—Four white female Wistar rats each with one spontaneous mammary fibroadenoma. These animals had littered from 3 to 5 times, and in two (R 2479 and R 2489) the tumors appeared during the last pregnancy. In one of these (R 2479) autotransplants were introduced into both axillae and the right groin, the primary tumor being left *in situ* in the left groin. Two mgm. of dimenformon ( $\alpha$ -estradiol) were injected in divided doses during 3 weeks. The primary fibroadenoma and the autotransplants grew rapidly in the next 2 weeks, becoming adenomas, and the nipples became prominent. At the end of this time, 18 mgm. of progesterone were injected subcutaneously in divided doses during the next 9 weeks. Interval biopsies showed a gradual recession of the tumors and a shrinkage of their ducts and glands, with increasing fibrosis in the stroma. An additional 1 mgm. of estradiol restored their growth rate and they now showed microscopically a decided duct hyperplasia. At this stage 15 mgm. of testosterone propionate, injected subcutaneously in divided doses during 8 weeks, again caused recession with the microscopic appearance of epithelial necrosis. The ovaries and thyroid were involuted, the adrenals and pituitary decidedly enlarged. A hydrosalpinx of the right tube was present.

In the second rat (R 2489) with a spontaneous tumor and autotransplants 13 mgm. of progesterone were injected in 3 weeks. The primary tumor gradually diminished in size, grew harder, and showed involution of the glands and ducts (Figs. 1 and 2). The autotransplants did not grow. Injection of 1 mgm. of  $\alpha$ -estradiol, after a second autotransplantation, stimulated the growth of the primary tumor and autotransplants after 6 weeks (Fig. 3). When the growth was

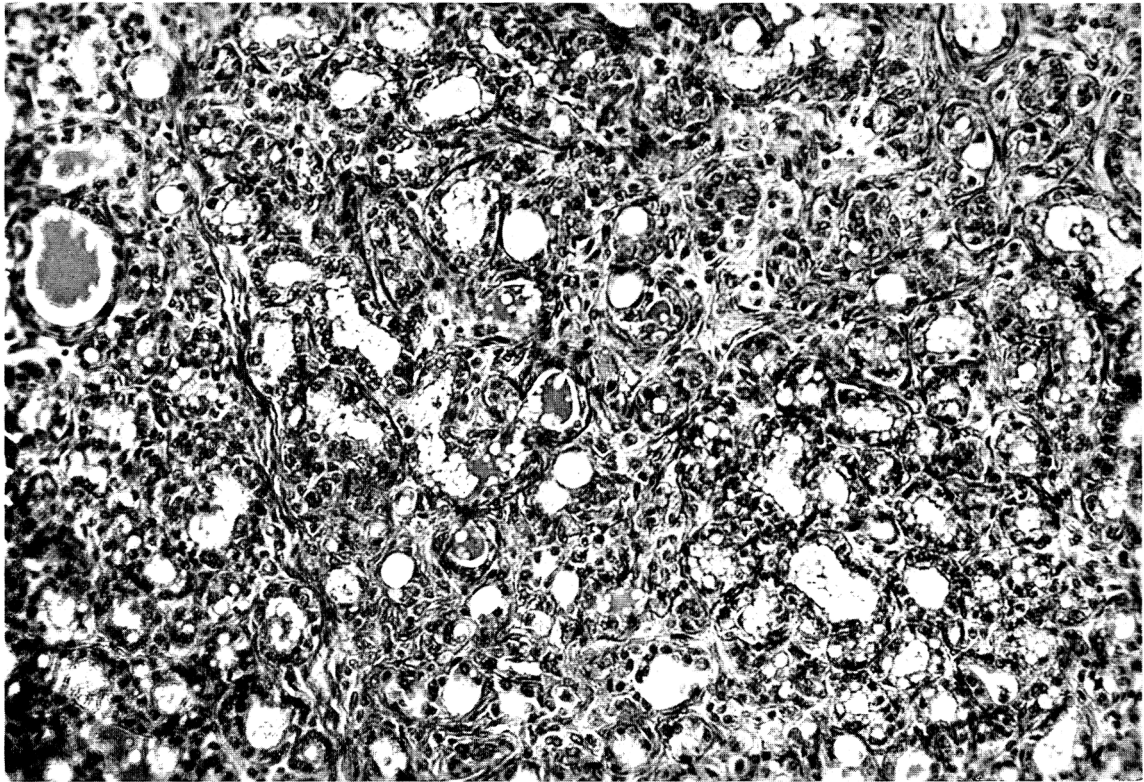


FIG. 1.—Spontaneous mammary adenofibroma in an untreated female white rat (R 2489). Mag. about  $\times 300$ .

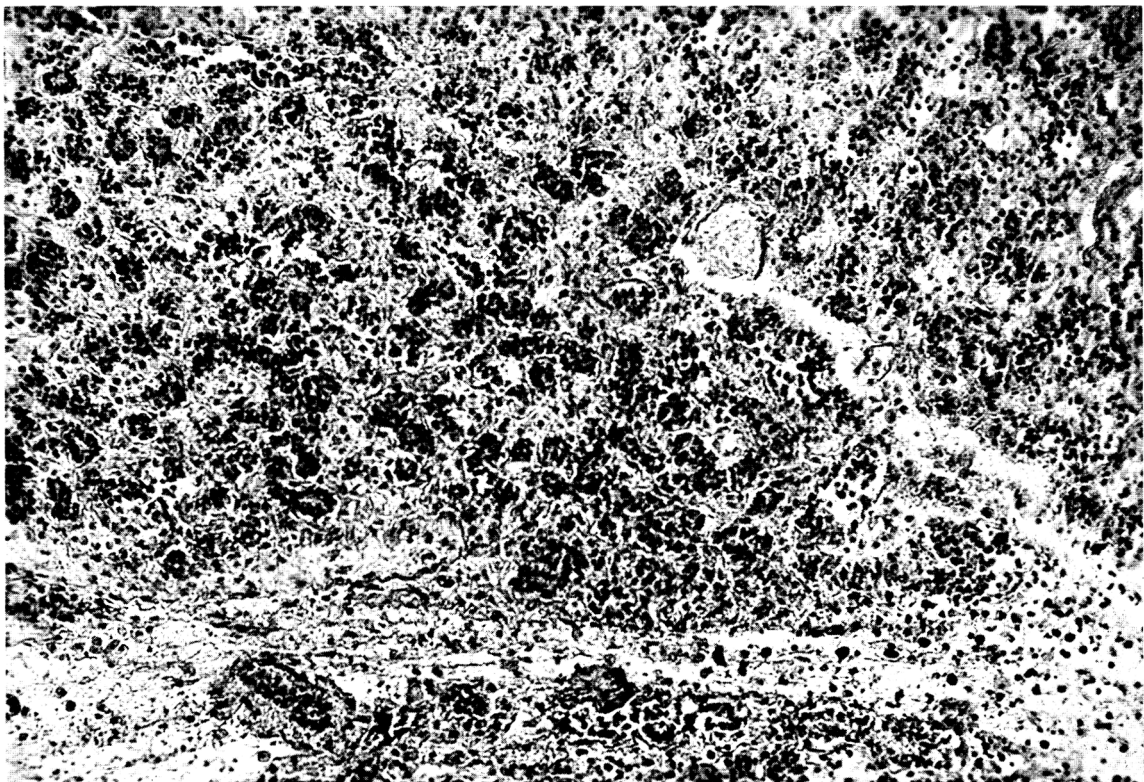

FIG. 2.—The same tumor after the subcutaneous injection of 18 mgm. of progesterone. Mag. about  $\times 300$ .

established, the injection of 10 mgm. of testosterone propionate again caused a recession of the tumors. Alternating the injections of progesterone and testosterone with estradiol produced further inhibition or stimulation of the primary tumor and the autotransplants.

In 2 rats, each with a spontaneous and autotransplanted fibroadenoma, receiving only progesterone, the tumor remained stationary but involution of the glandular fraction was apparent. Autotransplants did not grow.

*Group III.*—In 6 castrated females and 6 normal males the injection of progesterone was ineffective. The few growing tumors were fibromatous, and the takes were reduced to 16 per cent. It had been previously reported that the administration of estrogen to female castrates restored the tumor takes to 54 per cent, and that the transplanted tumors remained fibroadenomas (7).

*Group IV.*—In 6 castrated males the transplanted tumors likewise became fibromas after the injection of 13 mgm. of progesterone. The fibroadenomas

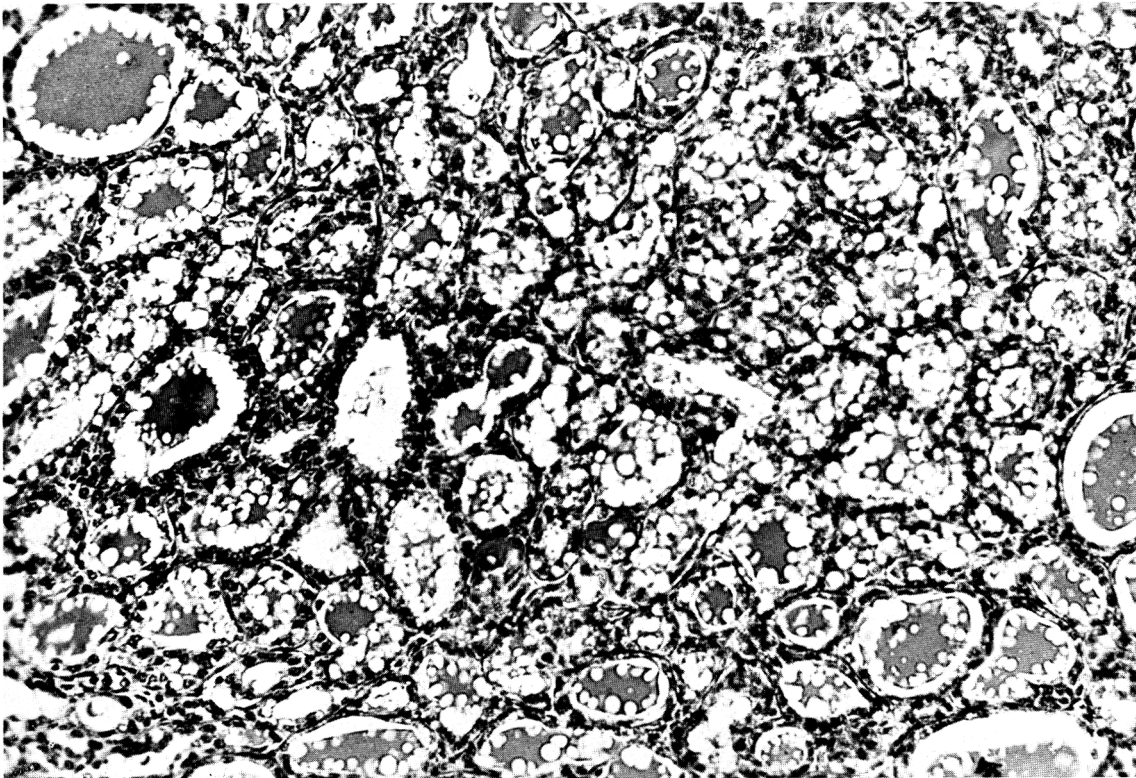


FIG. 3.—The same tumor as Figs. 1 and 2 after the subcutaneous injection of 2.5 mgm. of  $\alpha$ -estradiol. Mag. about  $\times 300$ .

*Group II.*—(a) Eighteen females with homotransplanted fibroadenoma were injected with 2.5 mgm. of estradiol followed by 18 mgm. of progesterone. In this group the effect of the estrogen on the benign tumors was evident, but there appeared to be no enhancing effect from the progesterone. The percentage of takes approximated the normal (66 per cent).

(b) Twenty females with homotransplanted fibroadenoma received 13 mgm. of progesterone each. In this group, the growth rate of the tumors was reduced (22 per cent) and most of them became cellular fibromas except in the 2 pregnant females, where the implanted fibroadenomas remained unchanged.

usually became more glandular in untreated castrated males (6, 7) and frequently formed adenomas when the male castrate was given estrogen.

In groups IIb, III, and IV the tumors were much smaller and harder, and the latent period was prolonged beyond 6 weeks. The action of progesterone on these growths resembled that of testosterone propionate on similar ones, and appeared to be indifferent or antagonistic to the action of estrogens. It required considerably larger doses of progesterone, as it did of testosterone, to overcome the action of estrogen.

Involution of the tumors, with regression and necrosis of the glands and ducts and an increased ten-

dency toward fibrosis, resulted when from 10 to 15 mgm. of testosterone propionate were administered in addition to progesterone. The number of takes in normal females was then reduced to 8.3 per cent. In 12 Wistar females inoculated with spontaneous fibroadenoma from a Wistar rat that had received progesterone, no growths resulted

#### DISCUSSION

The observations recorded here conform to some reports in the literature and are at variance with others.

Thus Corner (2) reported that progestin, injected into spayed rabbits, does not induce proliferation of the mammary gland. Turner and Frank (20) confirmed these findings in castrated male rabbits after estrogen followed by progestin. Turner and Schultze (22) found that stimulation of the mammary lobules did not occur in immature male and female castrated rats after luteal extracts were administered. Selye, Brown, and Collip (18) noted no effect in castrated females. Turner and Gomez (21) found progestin ineffective in stimulating growth. Nelson (14) modified his conclusion, at first (17) reporting stimulation and later (15) obtaining negative results from purified progestin. Lipschütz and Vargas (11, 12) described the prevention of experimentally produced uterine and extrauterine fibroids by the injection of testosterone and progesterone in guinea pigs. Nelson and Pfiffner (16) elicited notable hypertrophy of the mammary glands of immature castrated guinea pigs and male rabbits by injection of corpus luteum extract. Hartman and Speert (5) produced development of the mammary gland in castrated female monkeys after large doses (150 to 500 mgm.) of progesterone. Gardner and Hill (3) found that progestin stimulated duct growth in male and female mice. Astwood and Geschickter (1, 4) noted no effect on the mammary glands of rats after the administration of progesterone. Korenchevsky and Hall (10) found progesterone to inhibit uterine epithelial hyperplasia in estrinized rats.

Lyons and McGinty (13) reported that large doses of progesterone with small doses of estrone, given to immature male rabbits, inhibited mammary growth. An interesting observation by Smith and Werthessen pointed out the low pregnandiol values in chorioepithelioma (19).

The majority of investigators report a negative or inhibiting action of progesterone alone on normal mammary development, and stress the necessity of previous estrogen administration for complete physiologic development. No progestational effect has been noted on benign mammary fibroadenoma of the rat. In large doses, administered over a long period, progesterone seems to have an inhibitory effect on the

glandular component of these tumors. This action resembles one noted after the administration of testosterone to rats with similar tumors.

#### CONCLUSIONS

1. Progesterone inhibited the growth of the adenomatous portion of spontaneous rat mammary fibroadenoma. Shrinkage was followed by fibrosis.
2. Progesterone reduced the percentage of takes of auto- and homotransplants (66 to 22 per cent).
3. Eighteen mgm. of progesterone did not interfere with the stimulating effect of 2.5 mgm. of estrogen. Eighteen mgm. of progesterone inhibited the stimulating effect of 1 mgm. of estrogen.
4. Progesterone alone did not affect fibromas growing in castrated females or normal males.
5. Progesterone alone inhibited growth of the glandular portion of adenofibromas in castrated males.
6. Progesterone and testosterone in combination were effective in reducing the percentage of takes from 66.6 to 8.3 per cent, and in inhibiting the growth of the glandular fraction of the tumor.
7. Large doses of progesterone or testosterone were necessary to neutralize the stimulating effect of estrogen on growing fibroadenoma.
8. Rat fibroma, myxoma, and sarcoma were not inhibited by progesterone.
9. Progesterone did not hinder the growth of fibroadenomas in pregnant rats, no doubt because of the high estrogen content of the organism.
10. The action of progesterone on benign mammary fibroadenomas was unlike the progestational effect on the uterus and normal mammary gland.

#### REFERENCES

1. ASTWOOD, E. B., and GESCHICKTER, C. F. Changes in the Mammary Gland of the Rat, Produced by Various Glandular Preparations. *Arch. Surg.*, **36**:672-697. 1938.
2. CORNER, G. W. The Hormonal Control of Lactation. I. Non-Effect of the Corpus Luteum. *Am. J. Physiol.*, **95**:43-55. 1930.
3. GARDNER, W. U., and HILL, R. T. Effect of Progestin upon the Mammary Glands of the Mouse. *Proc. Soc. Exper. Biol. & Med.*, **34**:718-720. 1936.
4. GESCHICKTER, C. F., and ASTWOOD, E. B. The Relation of Oestrin and Other Hormones to Tumor Formation in the Breast. *Cancer Probl., Symposium, Science, suppl.*, **85**:76-85. 1937.
5. HARTMAN, C. G., and SPEERT, H. Action of Progesterone on the Genital Organs of the Unprimed Rhesus Monkey. *Endocrinology*, **29**:639-648. 1941.
6. HEIMAN, J. The Study of Benign Neoplasms of the Rat's Breast. *Am. J. Cancer*, **22**:497-524. 1934.
7. HEIMAN, J. Growth of Transplanted Mammary Fibroadenoma in Castrated Rats Injected with Hormones. *Am. J. Cancer*, **39**:172-184. 1940.
8. HEIMAN, J. The Effect of Androgens and Estrogens on Spontaneous Benign Mammary Tumors in the Rat. *Am. J. Cancer*, **40**:343-354. 1940.

9. HEIMAN, J., and KREHBIEL, O. F. The Influence of Hormones on Breast Hyperplasia and Tumor Growths in White Rats. *Am. J. Cancer*, **27**:450-473. 1936.
10. KORENCHESKY, V., and HALL, K. The Effect of Progesterone on the Metaplasia of the Uterine Epithelium of Rats Injected with Oestrogens. *J. Obst. & Gynaec. Brit. Emp.*, **45**:22-29. 1938.
11. LIPSHÜTZ, A., MURILLO, R., and VARGAS, L., JR. Antitumorigenic Action of Progesterone. *Lancet*, **2**:420-421. 1939.
12. LIPSHÜTZ, A., and VARGAS, L., JR. Prevention of Experimental Uterine and Extrauterine Fibroids by Testosterone and Progesterone. *Endocrinology*, **28**:669-675. 1941.
13. LYONS, W. R., and MCGINTY, D. A. Effects of Estrone and Progesterone on Male Rabbit Mammary Glands. I. Varying Doses of Progesterone. *Proc. Soc. Exper. Biol. & Med.*, **48**:83-86. 1941.
14. NELSON, W. O. Endocrine Control of the Mammary Gland. *Physiol. Rev.*, **16**:488-526. 1936.
15. NELSON, W. O. Studies on the Physiology of Lactation. VI. The Endocrine Influences Concerned in the Development and Function of the Mammary Gland in the Guinea Pig. *Am. J. Anat.*, **60**:341-359. 1937.
16. NELSON, W. O., and PFIFFNER, J. J. An Experimental Study of the Factors Concerned in Mammary Growth in Milk Secretion. *Proc. Soc. Exper. Biol. & Med.*, **28**:1-2. 1930.
17. NELSON, W. O., and PFIFFNER, J. J. Studies on the Physiology of Lactation. I. The Relation of Lactation to the Ovarian and Hypophyseal Hormones. *Anat. Rec.*, **51**:51. 1931.
18. SELYE, H., BROWNE, J. S. L., and COLLIP, J. B. Effect of Combined Administration of Oestrone and Progesterone in Adult Ovariectomized Rats. *Proc. Soc. Exper. Biol. & Med.*, **34**:198-200. 1936.
19. SMITH, J. T., and WERTHESSEN, N. T. Chorioepithelioma Associated with Tubal Pregnancy and Pulmonary Metastases. High Gonadotropin and Low Pregnandiol Values. *Am. J. Obst. & Gynec.*, **41**:153-156. 1941.
20. TURNER, C. W., and FRANK, A. H. The Relation between the Estrus-Producing Hormone and a Corpus Luteum Extract on the Growth of the Mammary Gland. *Science*, **73**:295-296. 1931.
21. TURNER, C. W., and GOMEZ, E. T. The Experimental Development of the Mammary Gland. I. The Male and the Female Albino Mouse. II. The Male and the Female Guinea Pig. *Missouri Agr. Exper. Sta. Research Bull.*, No. 206. 1934.
22. TURNER, C. W., and SCHULTZE, A. B. A Study of the Causes of the Normal Development of the Mammary Glands of the Albino Rat. *Missouri Agr. Exper. Sta. Research Bull.*, No. 157. 1931.